

Complications of Rhinoplasty

Joshua B. Surowitz, MD*, Sam P. Most, MD

KEYWORDS

• Rhinoplasty • Septorhinoplasty • Complications

KEY POINTS

- Meticulous history, physical examination, and standardized photographic documentation are central to preoperative evaluation and surgical planning for rhinoplasty.
- Photographic documentation is very useful to help illustrate preexisting preoperative asymmetries, and the surgeon must document these in the physical examination and discuss them with the patient.
- As with any surgery, any complications should be openly discussed with the patient.
- Appropriate preoperative counseling regarding all risks, benefits, and alternatives is critical.
- The surgeon must have a comprehensive understanding of nasal anatomy and effects of surgical maneuvers to help avoid complications.

OVERVIEW

Rhinoplasty is a very common surgical procedure among facial and general plastic surgeons. It may be performed for functional and aesthetic reasons. It is a highly technically challenging procedure, because the surgeon must pay careful attention to both form and function. An aesthetically pleasing nose without the ability to breathe is a surgical failure. Some complications may occur intraoperatively, whereas others may occur postoperatively during wound healing and contracture. Therefore, some complications may not become evident until months to years after surgery.

ASYMMETRIES

Asymmetries of the bony pyramid can occur for multiple reasons, including discrepancies in osteotomies between sides, asymmetric dorsal reduction, and persistence of preoperative asymmetries. A greenstick fracture, with failure to fully

osteotomize, may result in either failure to fully mobilize the nasal bone or the nasal bone lateralizing from memory.

Asymmetries of the middle third are also often multifactorial. A septal deviation that was not causing asymmetry before dorsal reduction may become “unmasked” after dorsal reduction, and thereby cause asymmetries of the middle vault. Asymmetric dorsal reduction of the middle third can also occur. Palpation of the dorsum with moistened gloves allows careful assessment of the underlying anatomy after dorsal reduction.

Establishing symmetry at the tip is highly dynamic and requires an understanding of all major and minor tip support elements, as shown in **Table 1**.¹ Careful attention to tip suture technique and proper suture placement will help minimize tip asymmetries. Preexisting asymmetries of the medial and lateral crura may not be evident until other tip dynamics are altered. Similar to the middle third, a septal deviation that was not causing any asymmetry preoperatively may become “unmasked” as a result of

Disclosures: The authors have nothing to disclose.

Division of Facial Plastic and Reconstructive Surgery, Stanford Department of Otolaryngology/Head and Neck Surgery, 801 Welch Road, Stanford, CA 94305, USA

* Corresponding author.

E-mail address: jsurowitz@ohns.stanford.edu

Facial Plast Surg Clin N Am 21 (2013) 639–651

<http://dx.doi.org/10.1016/j.fsc.2013.07.003>

1064-7406/13/\$ – see front matter © 2013 Elsevier Inc. All rights reserved.

Table 1
Complications of rhinoplasty

Complication	Cause	Avoidance	Correction
Asymmetry of the bony vault	Asymmetric osteotomies	Meticulous attention to osteotomies	Percutaneous osteotomies
Asymmetry of the middle vault	Unmasked dorsal septal deviation after dorsal reduction	Recognition of septal deviation	Crushed cartilage camouflage grafts
Tip asymmetry	Asymmetric tip sutures Unmasked caudal septal deviation	Meticulous attention to suture technique Meticulous inspection	Revision Possible placement of septal extension graft Possible repositioning of caudal septum with swinging door, secure to nasal spine with suture
Overresection of nasal bones	Overaggressive resection	Judicious bony dorsal reduction	Placement of dorsal onlay graft
Open roof deformity	Bony dorsal reduction	Judicious bony dorsal reduction when no osteotomies are planned, but unavoidable when narrowing of the bony base is planned	Lateral osteotomies to close open roof
Rocker deformity	Continuation of osteotomies into frontal bone	Meticulous planning of osteotomies and continuous palpation/inspection	Percutaneous osteotomies
Stair step deformity	Improper placement of lateral osteotomy anterior to the ascending process of the maxilla	Meticulous planning of osteotomies and continuous palpation/inspection	Percutaneous osteotomies
Pollybeak deformity	Overresection of nasal bones Underresection of dorsal septum (anterior septal angle)	Meticulous planning of dorsal reduction, both bony and cartilaginous dorsum	Dorsal onlay camouflage graft Appropriately match cartilaginous dorsal reduction to that of bony dorsal reduction May require revision
	Postoperative soft tissue scar formation	Avoid overaggressive dorsal reduction in thick-skinned patients	Kenalog injections postoperatively
Inverted V deformity	Upper lateral cartilages drop inferior and posterior, causing show of the nasal bones and dorsal septum This results from failure to repair the upper laterals to the dorsal septum after dorsal reduction	Repair upper lateral cartilages to dorsal septum after dorsal reduction Use of spreader grafts or autospreader grafts	Revision with use of spreader grafts (if upper lateral cartilage present), possible onlay crushed cartilage camouflage grafts, consider osteotomies to narrow the bony base if this is a contributing factor

Saddle nose deformity	Overaggressive dorsal reduction with septoplasty, resulting in a dorsal strut that is inadequate to support cartilaginous dorsum	Maintain 1.5-cm dorsal strut	Revision with dorsal onlay camouflage graft (minor cosmetic deformity) and rib cartilage graft reconstruction (severe cases)
Bossae	Overaggressive cephalic trim of lateral crura	Note predisposing factors for bossae formation (see below), avoid overaggressive resection	Revision with structural grafting of lateral crura (strut grafts), crushed cartilage, and/or temporalis fascia camouflage grafts
Visible grafts	Thin skin	Note thin skin preoperatively and place temporalis fascia overlay grafts to camouflage	Revision with possible graft removal and/or placement of temporalis fascia for contour smoothing and camouflage
Pinched tip	Overresection of lateral crura during cephalic trim	Spare 6- to 7-mm rim strip	Lateral crural strut grafts, possible crushed cartilage grafts for camouflage
	Malpositioning of lateral crura	Ensure appropriate orientation and positioning of lateral crura	Removal/revision of any offending tip sutures, possible lateral crural strut grafting, possible repositioning of lateral crura
	Contracture from wound healing	Unavoidable, must preoperatively counsel patient about this risk and document having done so	Revision surgery with one or more of the above maneuvers
Poorly defined tip	Overaggressive tip deprojection in thick-skinned patient	Avoid overaggressive deprojection	Judicious superficial nasalis aponeurotic system (SNAS) excision intraoperatively, Kenalog injections postoperatively
Nostril asymmetry	Altered caudal septum, medial, intermediate, and lateral crura dynamics from intraoperative suture technique or alteration	Meticulous attention to symmetric placement of sutures, such as tip and tongue in groove sutures	Revision, with correction of underlying offending cause
Alar retraction	Overly tight closure of marginal incision		Remove/revise offending sutures
	Overresection of lateral crura during cephalic trim		Lateral crural strut grafts, possible alar rim grafts (minor cases), auricular composite grafts (severe cases)
	Malpositioning of the lateral crura		Repositioning of the lateral crura, lateral crural strut grafts, possible alar rime grafts (minor cases), auricular composite grafts (severe cases)
	Overly tight lateral crural spanning sutures		Removal/revision of any offending tip sutures
	Contracture from wound healing		Revision surgery with one or more of the above maneuvers

(continued on next page)

Table 1 <i>(continued)</i>			
Complication	Cause	Avoidance	Correction
Columellar retraction	Overresection of the caudal septum	Avoid overresection	Caudal septal extension graft, columellar strut graft, columellar plumping graft
	Excessive setback of the medial crura during tongue-in-groove	Avoid excessive setback	Revise tongue-in-groove, consider columellar plumping graft Septocolumellar suture can be used to help prevent contracture during wound healing
Columellar and alar base scar formation	Wound healing	Meticulous wound closure	Kenalog injections with revision reserved for severe cases
Nasal obstruction	External nasal valve collapse	Maintain integrity and appropriate position of lateral crura, avoid overaggressive narrowing of the alar base	Lateral crural strut grafts, possible alar rim grafts
	Internal nasal valve collapse	Avoid overaggressive narrowing of the bony base, use spreader grafts or autospreader grafts to maintain patency	Spreader or autospreader grafts
	Septal deviation Intranasal synechia	Appropriately address any septal deviation Careful soft tissue handling and fastidious wound closure	Septoplasty Lysis of synechia
	Recurvature of the lateral crura	Recognize contribution to the patency of the nasal airway	Lateral crural strut grafts
Septal perforation	Opposing mucoperichondrial lacerations	Meticulous elevation of mucoperichondrial flaps to prevent opposing lacerations	Place fascia or crushed cartilage graft interposed between lacerations
	Septal hematoma	Placement of septal whip sutures and use of removable soft silastic intranasal splints, prophylactic mucoperichondrial flap incision to allow drainage of any accumulated blood	Incision and drainage
Costal cartilage (autograft and homograft) warping	Intrinsic property of cartilage	Concentric carving	Revision
Pneumothorax after costal cartilage harvest	Injury to the pleura	Harvest cartilage in subperichondrial plane	Close wound under water seal with positive pressure ventilation

surgical maneuvers, with resultant tip asymmetry or deviation. Contracture of the skin soft tissue envelope can also result in asymmetry of the tip over time.

Edema of the soft tissue envelope can make asymmetries and irregularities difficult to discern intraoperatively. Thus, careful marking before injection is paramount. Asymmetries can be minimized through judicious inspection from the top of the patient's head and through careful palpation using sterile saline-moistened gloves.

THE BONY PYRAMID

Overresection of the Nasal Bones

Overresection of the nasal bones can be avoided through judicious dorsal reduction, as seen in **Fig. 1**. Notice that this patient also has a pollybeak deformity, which is discussed later. More bone may easily be removed, whereas replacement after overresection presents a more challenging scenario.

Open Roof Deformity

An open roof is a normal consequence of dorsal reduction. Failure to close an open roof with appropriate osteotomies will result in a "flat top" appearance to the bony pyramid, as seen in **Fig. 2**. Edema of the soft tissue envelope can mask an open roof deformity on visual inspection.

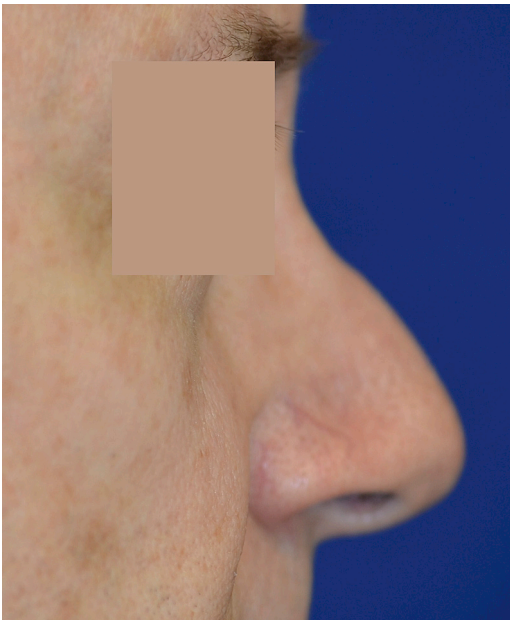

Fig. 1. Overresected nasal bones after prior rhinoplasty. Also note prominent pollybeak.

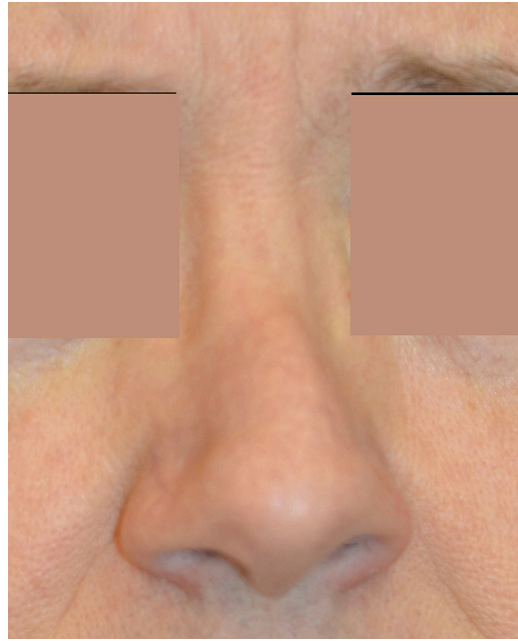

Fig. 2. Open roof deformity after prior rhinoplasty from failure to close with osteotomies.

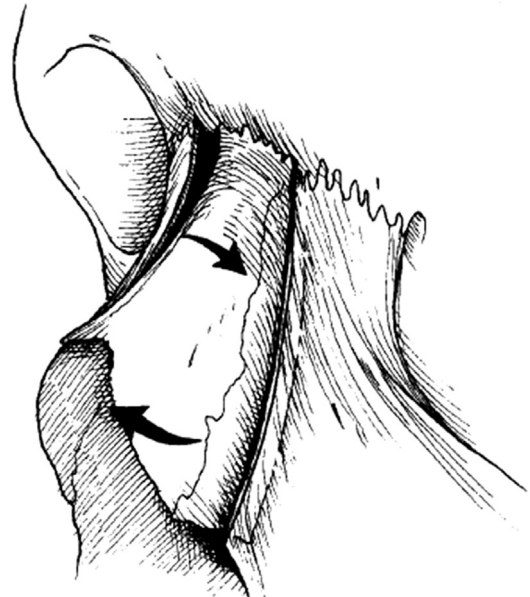


Fig. 3. Rocker deformity with osteotomies continuing into frontal bone. Note superior aspect "rocking" laterally when bony base is medialized. (From Toriumi DM, Hecht DA. Skeletal modifications in rhinoplasty. *Facial Plast Surg Clin North Am* 2000;8(4):424; with permission.)

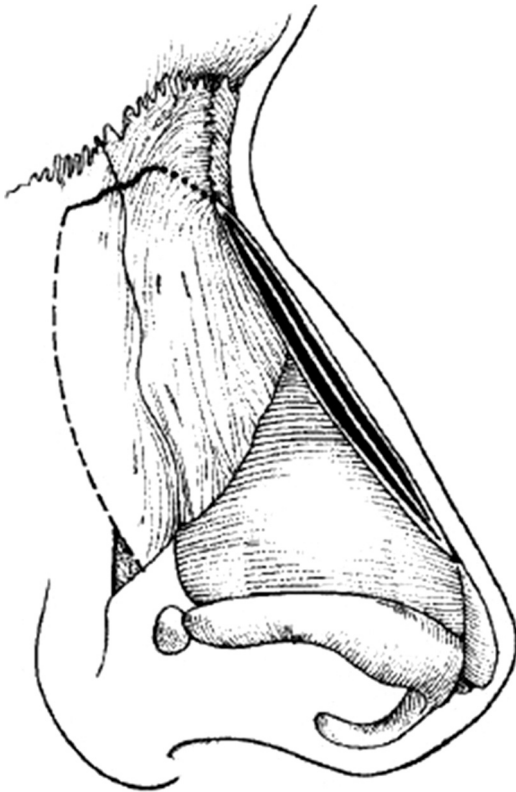


Fig. 4. Appropriate placement of osteotomies is demonstrated. Note lateral osteotomy in high-low-high fashion, fading medial osteotomy, with controlled back-fracture connecting medial and lateral osteotomies. (From Toriumi DM, Hecht DA. Skeletal modifications in rhinoplasty. *Facial Plast Surg Clin North Am* 2000;8(4):422; with permission.)

Again, careful palpation will make this readily apparent to the surgeon. Medial and lateral osteotomies are used to close an open roof deformity, narrowing the bony pyramid.

Rocker Deformity

Rocker deformity results from carrying osteotomies too far superiorly up into the frontal bone without appropriate back fracture. On medialization of the nasal bones, the superior portion is cantilevered, or “rocked,” laterally, as shown in **Fig. 3**.² This deformity can be avoided through careful planning of one’s osteotomies. When performing an endonasal lateral osteotomy, the guarded portion of the osteotome is oriented laterally and the surgeon continually palpates during the osteotomization process. Should this complication be encountered, transverse percutaneous

osteotomies may be performed to create the appropriate controlled back fracture.

Stair Step Deformity

Stair step deformity is caused by placement of the lateral osteotomy anterior to the ascending process of the maxilla, resulting in a palpable step-off. The lateral osteotomy should be placed along the ascending process (also known as the frontal process) of the maxilla in the standard high-low-high fashion, which is illustrated **Fig. 4**.² Careful planning of the lateral osteotomies will help the surgeon avoid this complication. The guarded portion of the osteotome is oriented laterally, and the surgeon continually palpates during the osteotomization process. In addition to careful palpation, the surgeon must listen for the distinct sound made when the osteotomy is being placed in the correct location along the ascending process of the maxilla. Percutaneous perforating lateral osteotomies also lend a degree of safety. This problem is difficult to correct, and therefore stair step deformity must be avoided.

THE MIDDLE THIRD **Pollybeak Deformity**

Pollybeak deformity results when the lower third of the dorsum is more projected than the tip.

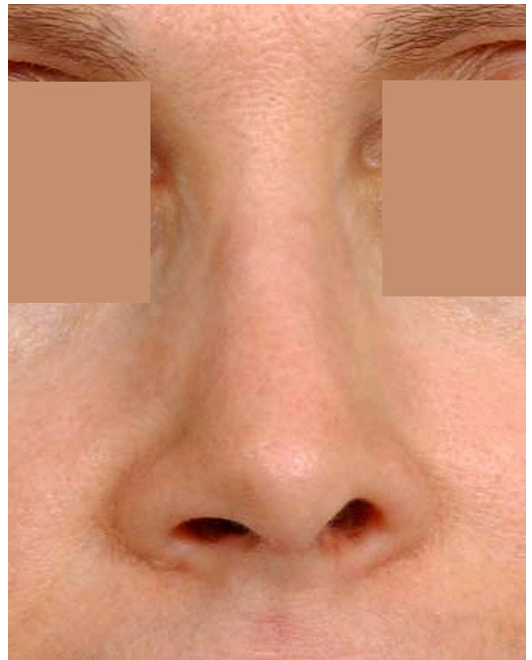


Fig. 5. Inverted V deformity is noted with prominence of the bony base and narrowing of the middle third.

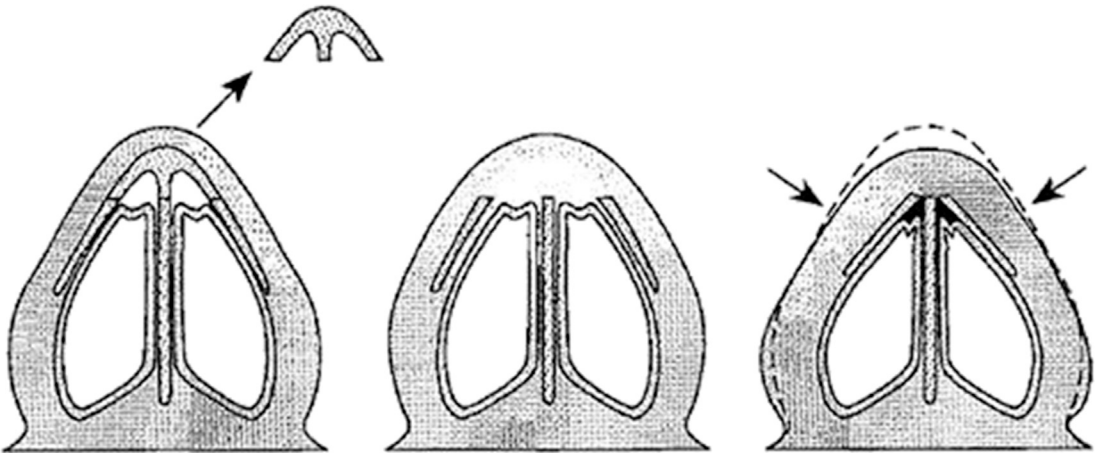


Fig. 6. Noted dorsal narrowing after cartilaginous dorsal reduction. (From Toriumi DM. Management of the middle nasal vault in rhinoplasty. *Facial Plast Surg Clin North Am* 1995;2(1):18; with permission.)

This is seen in **Fig. 1**. Overresection of the bony pyramid, underresection of the cartilaginous middle third (specifically the anterior septal angle), and supratip fibrosis deep to the soft tissue envelope can all result in pollybeak.¹ The first 2 are preventable, whereas the third occurs postoperatively in the setting of wound healing. Additionally, loss of tip support with subsequent tip ptosis can result in a relative pollybeak. Palpation allows the surgeon to assess the dorsum and to

determine if additional resection is necessary. Soft tissue pollybeak can be addressed with Kenalog injections to the affected area. The senior author prefers to use a very conservative Kenalog 10 mixed 1:10 or 1:5 with 1% lidocaine with 1:100,000 epinephrine. It is critical that all Kenalog be injected deep to the dermis to avoid dermal thinning. Overaggressive injection can itself cause divots from dermal or cartilaginous injury.

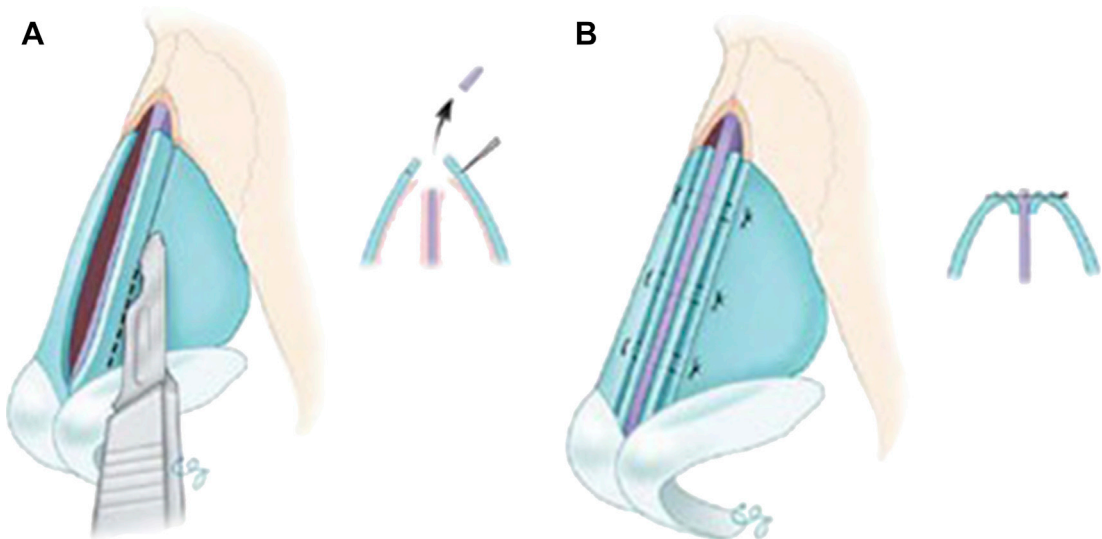


Fig. 7. Autospreader technique is shown. Upper lateral cartilage is scored (A), subsequently folded on itself and suture repaired to the dorsal septum (B). (From Yoo S, Most SP. Nasal airway preservation using the autospreader technique: analysis of outcomes using a disease-specific quality-of-life instrument. *Arch Facial Plast Surg* 2011;13(4):232; with permission.)

Inverted V Deformity

The inverted V deformity results from accentuated visibility of the caudal margins of the nasal bones after dorsal reduction, as seen in **Fig. 5**. As illustrated in **Fig. 6**, dorsal reduction causes narrowing of the cartilaginous dorsal width.³ As a result, the upper lateral cartilages become displaced inferiorly and posteriorly, thereby accentuating the caudal margin of the nasal bones.⁴⁻⁶ This deformity is further exaggerated if the bony base is not appropriately narrowed after dorsal reduction. Repair of the upper lateral cartilages to the dorsal septum and use of spreader grafts will help prevent this.⁶ The senior author routinely uses the autospreader upper lateral turn-in flaps, which are shown in **Fig. 7**.⁷

Saddle Nose Deformity

The saddle nose deformity may be the result of overresection of the quadrangular cartilage with insufficient dorsal strut. A postoperative saddle deformity is seen in **Fig. 8**. Inadvertent disarticulation of the keystone area, in which the quadrangular cartilage fuses superiorly with the perpendicular plate of the ethmoid, may also result

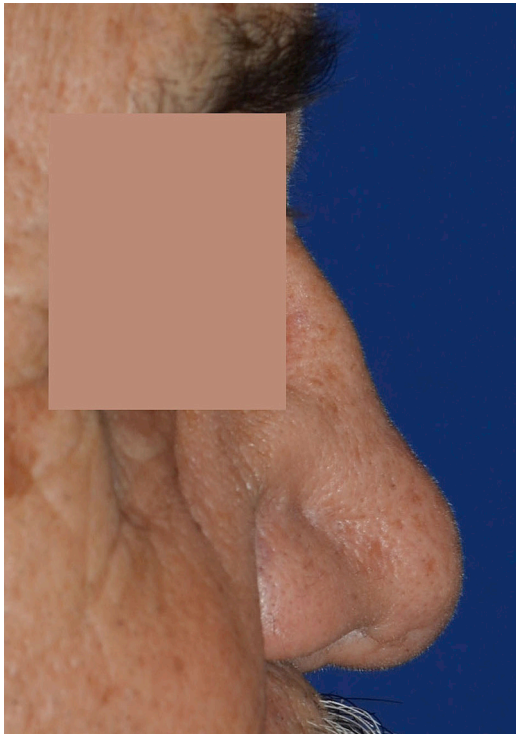

Fig. 8. Saddle nose deformity after prior rhinoplasty.

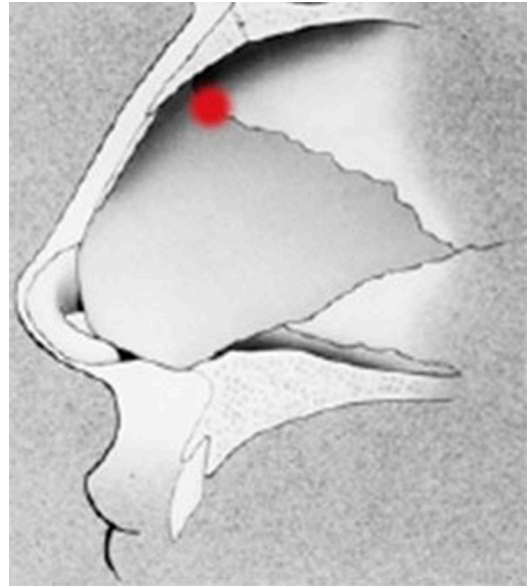


Fig. 9. The keystone area is highlighted in red. (From Tardy ME, Toriumi DM Jr, Hecht DA. Functional and aesthetic surgery of the nose. In: Papel ID, editor. Facial plastic and reconstructive surgery. 2nd edition. Thieme; New York: 2002. p. 370; with permission.)

in saddling. The keystone is shown in **Fig. 9**.⁸ Extracorporeal septoplasty is particularly prone to this and can be avoided using the anterior septal reconstruction technique.⁹

Saddle nose deformity can be difficult to correct and is best avoided. A mild saddle deformity may be corrected with crushed cartilage camouflage dorsal onlay grafting. If disarticulation of the keystone is noted intraoperatively, rib cartilage graft may be used for reconstruction, provided the patient has previously consented.

TIP AND ALA *Bossae*

Bossae, as illustrated in **Fig. 10**, are the result of visible flexing and buckling of the alar cartilage. These deformities tend to become evident months to years postoperatively.¹⁰ Patients at risk for tip bossae are those with thin skin, strong alar cartilages, and tip bifidity.^{10,11} Bossae can be avoided through maintaining the strength and integrity of the alar cartilage, using structural grafting when necessary, and symmetric reconstitution of the domal subunit with tip sutures.¹² Temporalis fascia or crushed cartilage may also be used in thin-skinned patients to help camouflage any irregularities.

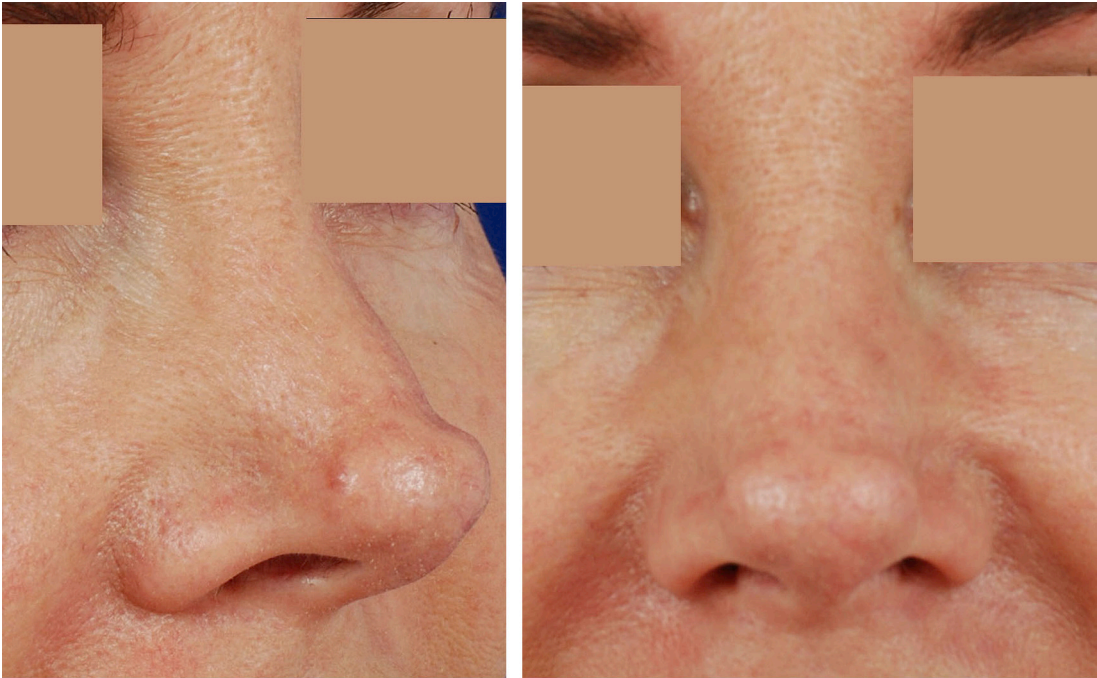

Fig. 10. Bossae are seen after prior rhinoplasty.

Visible Grafts

In thin-skinned individuals, tip grafts can become visible over time as the skin soft tissue envelope contracts and thins. Therefore, avoiding tip grafts in very thin-skinned individuals is preferable, because this complication is often noted at a later date, after edema has decreased and the skin soft tissue envelope has begun contracting, and must be addressed with formal revision. The authors often use temporalis fascia as a camouflage graft in thin-skinned patients if grafts must be used.

Pinched Tip

A pinched tip may result from overaggressive cephalic resection of the lateral crura, which results in weakening of the remaining rim strip (**Fig. 11**).¹³ Care must be taken to avoid overresection during cephalic trim. The senior author preserves at least a 7-mm rim strip to avoid overresection during cephalic trim. Malpositioning of the lateral crura, with the caudal border placed significantly inferior to the cephalic border, may similarly result in a pinched tip, as described by Toriumi and Checcone^{14,15} and illustrated in **Fig. 12**. Lateral crural repositioning and lateral crural strut grafts may be used to facilitate appropriate orientation of the lateral crura.^{14–16}

Poorly Defined Tip

The poorly defined or amorphous tip can occur in thick-skinned individuals after tip deprojection and suture modification. Recognizing thick skin preoperatively and avoiding overaggressive deprojection in thick-skinned individuals is key. Judicious SNAS excision may be performed to help improve tip definition.

Nostril Asymmetries

Nostril asymmetries can occur from an unmasked septal deviation after caudal septal resection,

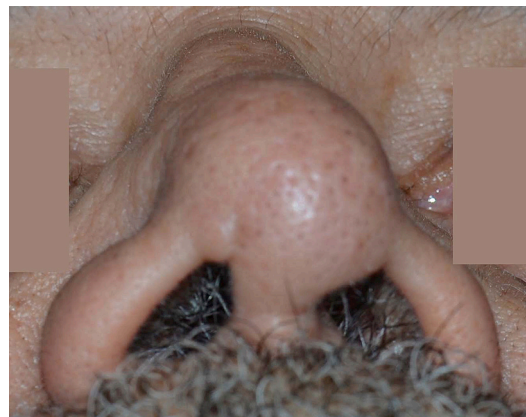


Fig. 11. Pinched tip after prior rhinoplasty.

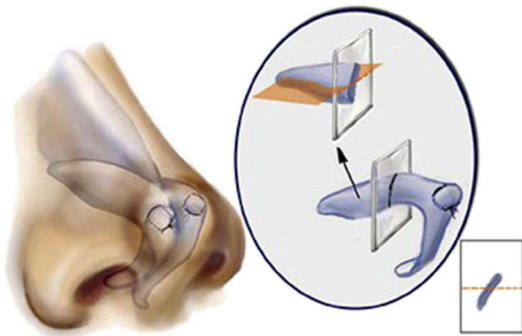


Fig. 12. Pinched tip may result from malpositioned lateral crura, with caudal margin positioned significantly inferior to cephalic margin. (From Toriumi DM. New concepts in nasal tip contouring. *Arch Facial Plast Surg* 2006;8(3):162; with permission.)

placement of a septal extension graft, or asymmetric tip modifications. It is important to recognize any preoperative nostril asymmetries and counsel patients appropriately in this regard. The authors routinely perform a nostril check before final closure to ensure appropriate symmetry.

Alar-Columellar Disproportion

Gunter and Friedman¹⁶ previously described the alar-columellar relationship and classification of related deformities. This article focuses on alar retraction, columellar retraction, and hanging columella. **Fig. 13** shows both alar retraction and a hanging columella.

Alar retraction may result from overly tight closure of marginal incisions, especially as one approaches the nasal facets. Careful attention to closure of the marginal incisions can help avoid Alar retraction. Overaggressive resection during cephalic trim can result in contracture of the lateral crura superiorly with time and wound healing, thereby causing alar retraction.¹⁷ Lateral crural spanning sutures placed too tightly may result in alar retraction.¹⁸ The orientation of the lateral crura is also of importance. As described by Toriumi and Checcone,¹⁵ the caudal margin of the lateral crura should lie in a plane almost horizontal and oriented just inferior to the cephalic margin. This technique prevents cephalic positioning of the lateral crura and helps support the alar rim. Alar retraction may be corrected with the use of alar rim grafts in minor cases (**Fig. 14**), with placement of ear composite grafts in more severe cases (**Fig. 15**).¹⁷

Columellar retraction may result from overaggressive resection of the caudal septum, medial crura, or excessive setback of the medial crura after placement of a tongue-in-groove suture.¹⁷ An overly resected caudal septum may be addressed

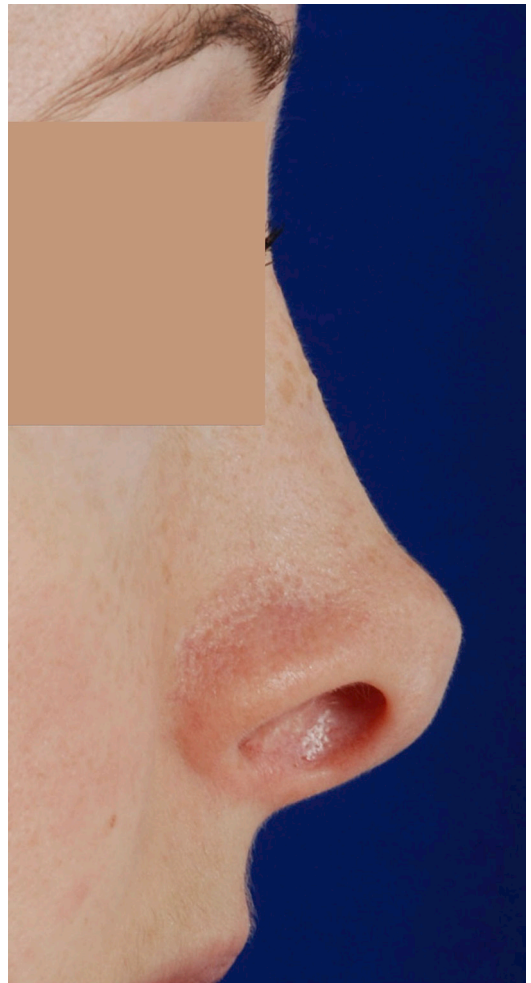


Fig. 13. Patient with both alar retraction and hanging columella after previous rhinoplasty.

with a caudal septal extension graft with or without tongue-in-groove repair of the medial crural footplates. Excessive setback after tongue-in-groove suture is best addressed through revision of the tongue-in-groove until the desired effect is achieved. Columellar struts or plumping grafts may also be helpful adjunctive measures in certain cases.

A hanging columella may result from placement of an overly large columellar strut graft, septal extension graft, or tip graft.¹⁷ Contributing anatomy includes the caudal septum, medial crura, intermediate crura, and membranous septum. Tip deprojection and decreased rotation may also contribute.¹⁷ Depending on the origin, a hanging columella can be addressed by selective resection of the caudal septum and tongue-in-groove suture technique.

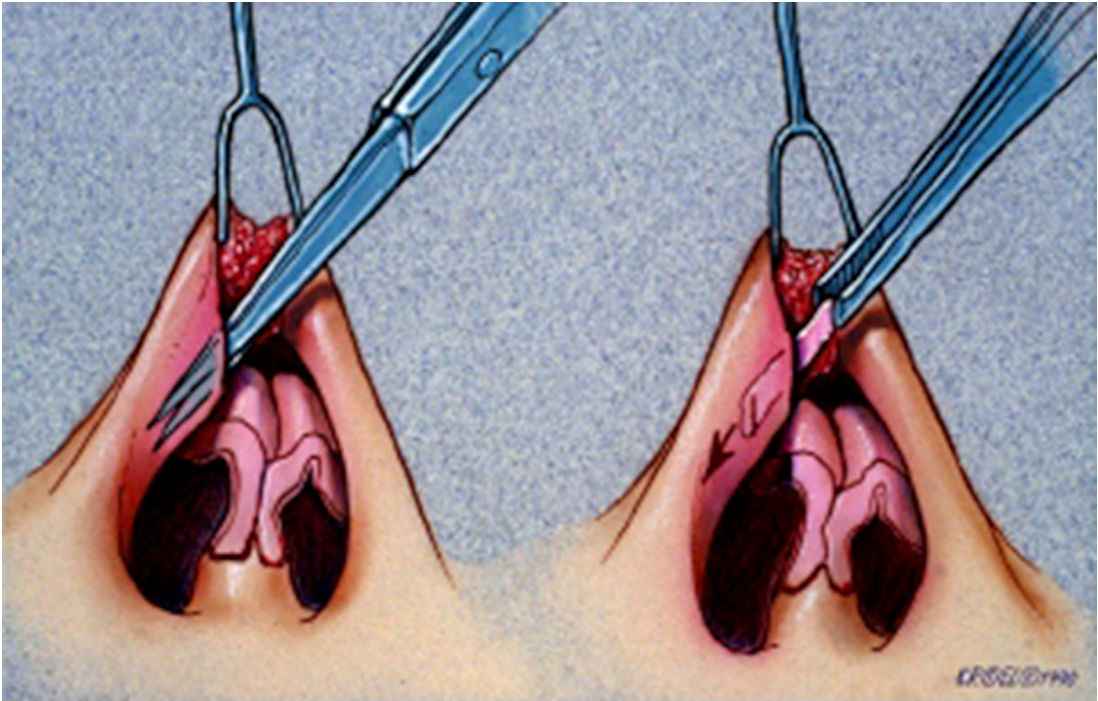


Fig. 14. Placement of alar rim grafts. (From Kridel RW, Chiu RJ. The management of alar columellar disproportion in revision rhinoplasty. *Facial Plast Surg Clin North Am* 2006;14(4):326; with permission.)

COLUMELLA AND ALAR BASE Scar Formation

Patients should be counseled about the potential for scar formation from the columellar incision in external rhinoplasty and with all alar base excisions. Unsightly columellar scars, hypertrophic scars, and keloids are very uncommon. Alar base excisions put the patient at risk for visible scar formation. The columellar incision is performed using an inverted V, so as to prevent scar formation.¹⁹

Meticulous attention to closure will help prevent columellar and alar base scar formation.

AIRWAY

Nasal obstruction can occur as a result of external nasal valve collapse, internal nasal valve collapse, septal deviation, and intranasal synechia formation. Weak lateral crura can be reinforced with lateral crural strut grafts.¹⁶ Spreader grafts may be used to widen the patency of the internal nasal

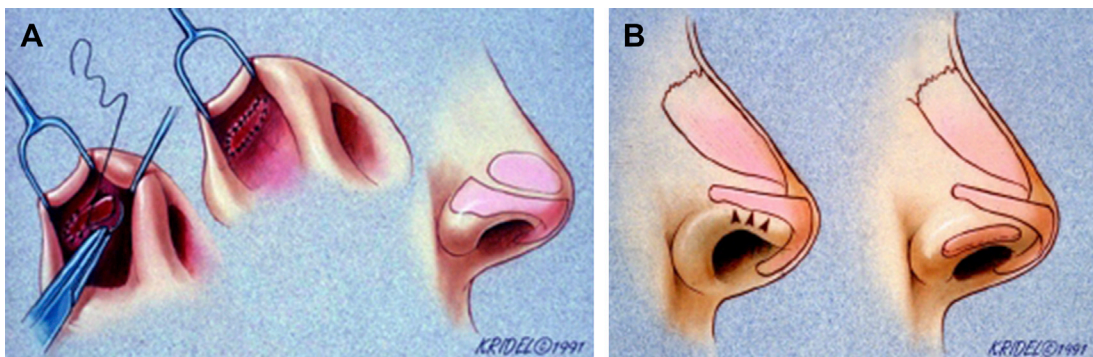


Fig. 15. Auricular composite grafts may be used to address alar retraction. These grafts may be placed at the level of the scroll (A) or at the caudal margin of the lateral crura (B). (From Kridel RW, Chiu RJ. The management of alar columellar disproportion in revision rhinoplasty. *Facial Plast Surg Clin North Am* 2006;14(4):319; with permission.)

valve.^{5,6,20,21} The senior author routinely uses autospreaders, as previously noted and illustrated in **Fig. 7.7**. Meticulous inspection of nostril symmetry, position of the caudal septum, and an understanding of the dynamics of the internal nasal valve will help minimize postoperative nasal obstruction. Recurvature of the lateral crura may also result in nasal airway obstruction, especially after maneuvers that narrow the nasal base, such as alar base excisions. Lateral crural strut grafts can be used to mitigate recurvature.

SEPTUM

Septal Perforation

Septal perforation is a known risk of any septal surgery and patients should be counseled in this regard. Prior septoplasty places the patient at a higher risk. Meticulous dissection of the mucoperichondrial flaps, with avoidance of lacerating the mucosa on both sides directly opposing one another will help minimize the risk of perforation. If bilateral opposing perforations occur intraoperatively, a crushed cartilage graft may be placed to allow mucosal healing.

Septal Hematoma

A septal hematoma is a risk of any septal surgery. These complications result when blood accumulates within any dead space between the elevated mucoperichondrial flaps. Septal hematomas predispose patients to infection and septal perforation. Use of transseptal whip sutures, placement of inferiorly based drainage incisions, and use of soft silastic removable intranasal splints will help minimize hematoma formation. Once a hematoma develops, it should be drained immediately.

COSTAL CARTILAGE GRAFTS

Costal cartilage grafts, including autologous and homologous, may become visible from warping over time. This deformity occurs from the intrinsic properties of cartilage. Concentric carving can mitigate this to some degree, but it is important to counsel patients regarding the risk of cartilage warping and subsequent irregularities or visibility of the graft.

Pneumothorax is a rare complication from autologous cartilage harvest. The risk of this is roughly 1% and can usually be managed without a chest tube. Should the surgeon encounter a pneumothorax, the injury is usually confined to the parietal pleura.²² Management consists of inserting a sterile red rubber catheter into the wound, placing the distal end of the catheter into sterile saline (as a water seal). Anesthesia then administers positive

pressure ventilation and the wound is closed as the catheter is removed. Patients should receive a postoperative chest radiograph and be admitted for observation, with a repeat chest radiograph on the morning of postoperative day one.

Homograft costal cartilage has a theoretical risk of resorption over time. Kridel and colleagues²³ found no significant difference between autologous and homologous cartilage with regard to resorption or infection. The senior author has been using homologous costal cartilage with good results in patients who are not candidates for autologous grafts because of age (ossification), severity of obstructive sleep apnea, other comorbidities, or patient preference. It is important to counsel patients regarding the theoretical risk of resorption, although this does not seem to manifest clinically.

SUMMARY

The dynamics of nasal aesthetics and function are very complex, and therefore the potential for complications are myriad. A thorough understanding of nasal anatomy and how various surgical maneuvers affect both form and function is imperative. Certain complications are within the surgeon's control, such as those related to technique, whereas those related to patient wound healing are out of the surgeon's control. Careful patient selection, history, physical examination, photo documentation, and patient counseling about appropriate expectations are important aspects of the surgery and should not be underestimated.

REFERENCES

1. Tardy ME Jr, Kron TK, Younger R, et al. The cartilaginous pollybeak: etiology, prevention, and treatment. *Facial Plast Surg* 1989;6(2):113–20.
2. Toriumi DM, Hecht DA. Skeletal modifications in rhinoplasty. *Facial Plast Surg Clin North Am* 2000;8(4):413–30.
3. Toriumi DM. Management of the middle nasal vault in rhinoplasty. *Facial Plast Surg Clin North Am* 1995;2(1):18.
4. Constantian MB. The incompetent external nasal valve: pathophysiology and treatment in primary and secondary rhinoplasty. *Plast Reconstr Surg* 1994;93(5):919–31 [discussion: 932–3].
5. Rohrich RJ, Hollier LH. Use of spreader grafts in the external approach to rhinoplasty. *Clin Plast Surg* 1996;23(2):255–62.
6. Sheen JH. Spreader graft: a method of reconstructing the roof of the middle nasal vault following rhinoplasty. *Plast Reconstr Surg* 1984;73(2):230–9.
7. Yoo S, Most SP. Nasal airway preservation using the autospreader technique: analysis of outcomes using

- a disease-specific quality-of-life instrument. *Arch Facial Plast Surg* 2011;13(4):231–3.
8. Tardy ME Jr, Toriumi DM, Hecht DA. Functional and aesthetic surgery of the nose. In: Papel ID, editor. *Facial plastic and reconstructive surgery*. 2nd edition. New York: Thieme; 2002. p. 370.
 9. Most SP. Anterior septal reconstruction: outcomes after a modified extracorporeal septoplasty technique. *Arch Facial Plast Surg* 2006;8(3):202–7.
 10. Kridel R, Yoon P, Koch R. Prevention and correction of nasal tip bossae in rhinoplasty. *Arch Facial Plast Surg* 2003;5(5):416–22.
 11. Gillman G, Simons R, Lee D. Nasal tip bossae in rhinoplasty. Etiology, predisposing factors, and management techniques. *Arch Facial Plast Surg* 1999;1(2):83–9.
 12. Brenner M, Hilger P. Thin skin rhinoplasty: aesthetic considerations and surgical approach. In: Azizzadeh B, Murphy MR, Johnson CM, et al, editors. *Master techniques in rhinoplasty*. Philadelphia: Elsevier; 2011. p. 331–4.
 13. Paun S, Trenite G. Correction of the pinched nasal tip deformity. In: Azizzadeh B, Murphy MR, Johnson CM, et al, editors. *Master techniques in rhinoplasty*. Philadelphia: Elsevier; 2011. p. 235–44.
 14. Toriumi DM. New concepts in nasal tip contouring. *Arch Facial Plast Surg* 2006;8(3):156–85.
 15. Toriumi DM, Checcone MA. New concepts in nasal tip contouring. *Facial Plast Surg Clin North Am* 2009;17(1):55–90, vi.
 16. Gunter JP, Friedman RM. Lateral crural strut graft: technique and clinical applications in rhinoplasty. *Plast Reconstr Surg* 1997;99(4):943–52 [discussion: 953–5].
 17. Kridel RW, Chiu. The management of alar columellar disproportion in revision rhinoplasty. *Facial Plast Surg Clin North Am* 2006;14(4):313–29, vi.
 18. Baker S. Suture contouring of the nasal tip. *Arch Facial Plast Surg* 2000;2(1):34–42.
 19. Davis RE. Proper execution of the transcolumellar incision in external rhinoplasty. *Ear Nose Throat J* 2004;83(4):232–3.
 20. Most SP. Trends in functional rhinoplasty. *Arch Facial Plast Surg* 2008;10(6):410–3.
 21. Most SP. Analysis of outcomes after functional rhinoplasty using a disease-specific quality-of-life instrument. *Arch Facial Plast Surg* 2006;8(5):306–9.
 22. Marin VP, Landecker A, Gunter JP. Harvesting rib cartilage grafts for secondary rhinoplasty. *Plast Reconstr Surg* 2008;121(4):1442–8.
 23. Kridel RW, Ashoori F, Liu ES, et al. Long-term use and follow-up of irradiated homologous costal cartilage grafts in the nose. *Arch Facial Plast Surg* 2009;11(6):378–94.