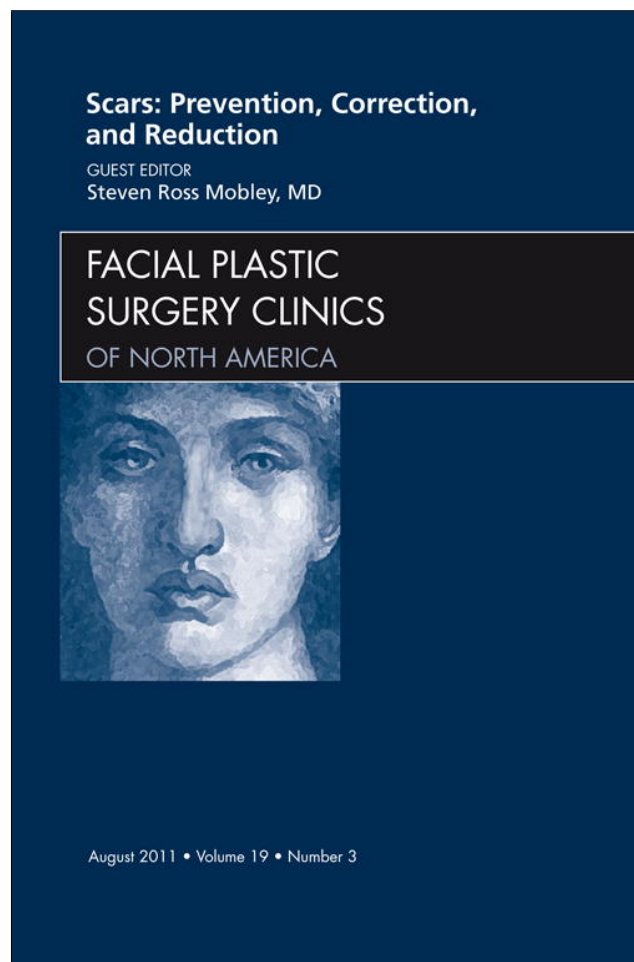

This article appeared in a journal published by Elsevier. The attached copy is furnished to the author for internal non-commercial research and education use, including for instruction at the authors institution and sharing with colleagues.

Other uses, including reproduction and distribution, or selling or licensing copies, or posting to personal, institutional or third party websites are prohibited.

In most cases authors are permitted to post their version of the article (e.g. in Word or Tex form) to their personal website or institutional repository. Authors requiring further information regarding Elsevier's archiving and manuscript policies are encouraged to visit:

<http://www.elsevier.com/copyright>

# Enhancement of Facial Scars With Dermabrasion

Joshua B. Surowitz, MD<sup>a,\*</sup>, William W. Shockley, MD<sup>b</sup>

## KEYWORDS

- Dermabrasion • Wound healing • Facial scars
- Facial trauma

Dermabrasion is a well-established method of skin resurfacing, used for both facial rejuvenation and scar revision. The earliest known use of dermabrasion dates back to Egypt, 1500 BC, when sandpaper was used to revise scars.<sup>1</sup> Many forms of skin resurfacing are available, including chemical peels, laser resurfacing, and mechanical resurfacing, known as *dermabrasion*. Dermabrasion results in the removal of the epidermis along with partial removal of the dermis. Dermabrasion devices consist of a powered hand piece and either a wire brush or diamond fraise. Although not viewed as “high tech” or glamorous, dermabrasion continues to be a popular adjunct to scar revision, with many benefits over other resurfacing options. As with any procedure, technical proficiency, experience, and understanding of its applications and limitations are paramount.

## PHYSIOLOGY OF WOUND HEALING

Understanding the physiology of wound healing is important when considering any skin resurfacing procedure. Wound healing occurs in progressive phases: the inflammatory phase, the proliferative phase, and the maturation phase; with significant overlap between the inflammatory and proliferative phases (**Fig. 1**).

### *Inflammatory Phase*

During the inflammatory phase, injury to endothelial cells results in exposure of subendothelial collagen,

which acts as a binding surface for aggregation of platelets and results in their activation. The extrinsic and intrinsic coagulation cascades then occur, ultimately resulting in the activation of thrombin, which converts fibrinogen to fibrin. Fibrin then acts as the substrate for further platelet aggregation, migration of inflammatory cells, and plasma proteins. The inflammatory phase initially involves a period of vasoconstriction, mediated by epinephrine, norepinephrine, prostaglandins, serotonin, and thromboxane. This stage is followed by vasodilation, which is activated by histamines, prostaglandins, kinins, and leukotrienes. Macrophages function in phagocytosis and also release chemotactic and growth factors, including transforming growth factor (TGF)- $\beta$ , basic fibroblast growth factor, epidermal growth factor, TGF- $\alpha$ , and platelet-derived growth factor, which is critical in endothelial cell and fibroblast proliferation.<sup>2–4</sup>

### *Proliferative Phase*

The proliferative phase begins within 24 hours of injury and has significant overlap with the inflammatory phase. Epithelial regeneration, fibroplasia, collagen formation, wound contraction, and neovascularization all occur during the proliferative phase. Epithelial regeneration begins within 24 hours of injury and is at its peak between 48 and 72 hours.<sup>5</sup> Reepithelialization occurs as a result of the migration of epithelial cells from the wound margins and from within adnexal

The authors have no conflicts of interest and nothing to disclose.

<sup>a</sup> Department of Otolaryngology/Head and Neck Surgery, University of North Carolina at Chapel Hill, G190, Physician's Office Building, CB 7070, Chapel Hill, NC 27599, USA

<sup>b</sup> Facial Plastic and Reconstructive Surgery, Department of Otolaryngology/Head and Neck Surgery, University of North Carolina School of Medicine, CB # 7070, G105 Physicians Office Building, 170 Manning Drive, Chapel Hill, NC 27599-7070, USA

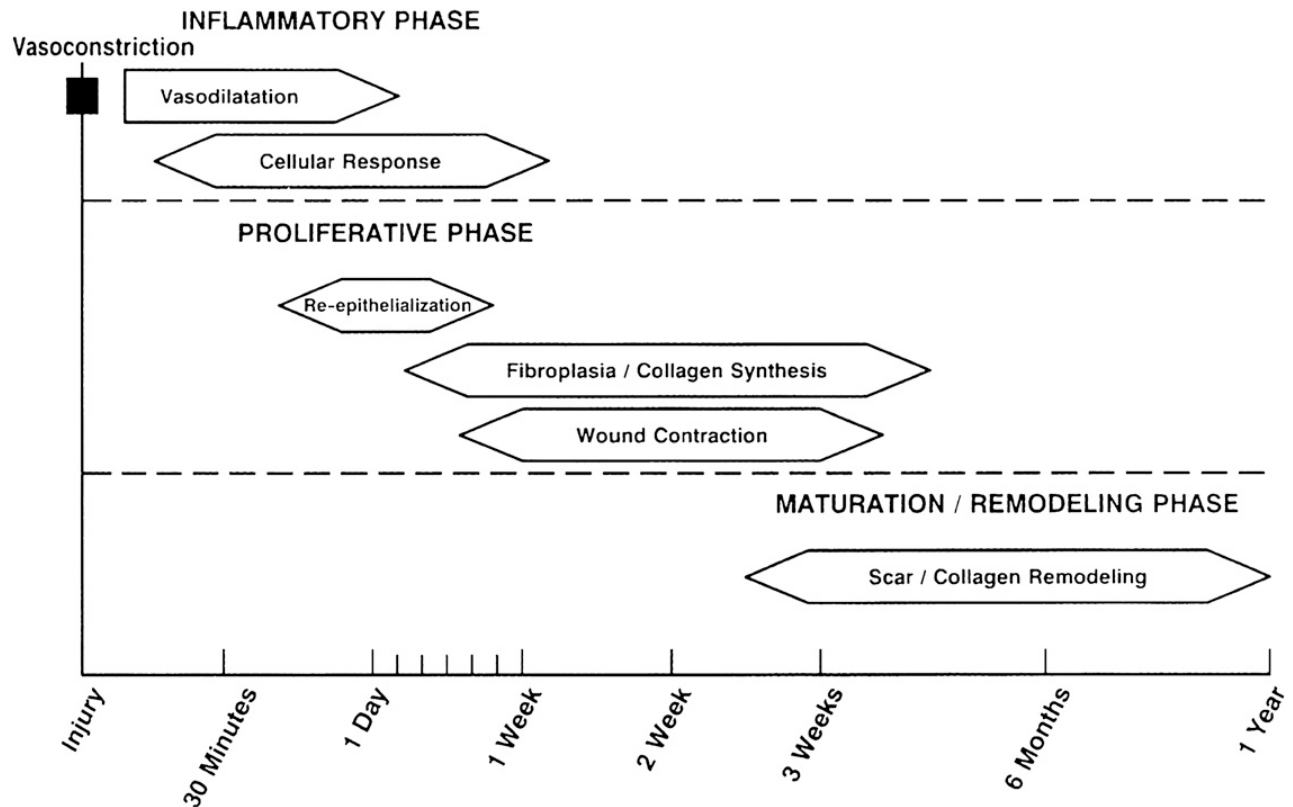
\* Corresponding author.

E-mail address: JSurowit@unch.unc.edu

Facial Plast Surg Clin N Am 19 (2011) 517–525

doi:10.1016/j.fsc.2011.05.013

1064-7406/11/\$ – see front matter © 2011 Elsevier Inc. All rights reserved.



**Fig. 1.** Phases of wound healing. (From Fisher E, Frodel J. Wound healing. In: Papel I, editor. Facial plastic and reconstructive surgery. New York: Thieme; 2009. p. 17; with permission.)

structures of the skin, which include sweat glands, hair follicles, and sebaceous glands.<sup>2,6</sup> Basal stem cells within the adnexae undergo differentiation and subsequent migration, which is why it is paramount to dermabrade only down as far as the superficial reticular dermis, otherwise epithelialization will be impaired and scarring may result (**Fig. 2**).<sup>5</sup> Apposition of advancing epithelial cells results in inhibition of further migration, and in stratification and differentiation.

Fibroplasia, which is the growth of fibroblasts within the wound, occurs 48 to 72 hours after injury and is associated with a significant increase in collagen synthesis, which is most prominent 4 days after injury.<sup>5,7</sup> In addition to collagen, fibroblasts also secrete elastin, fibronectin, glycosaminoglycans, and collagenase. Granulation tissue and neovascularization are also noted during the proliferative phase. Granulation tissue forms during the reepithelialization process, usually beginning at day 3 or 4, and continues until reepithelialization is complete. Wound contraction occurs as fibroblasts differentiate into myofibroblasts, reaching its maximum around 10 to 15 days after injury.<sup>5</sup>

### Maturation Phase

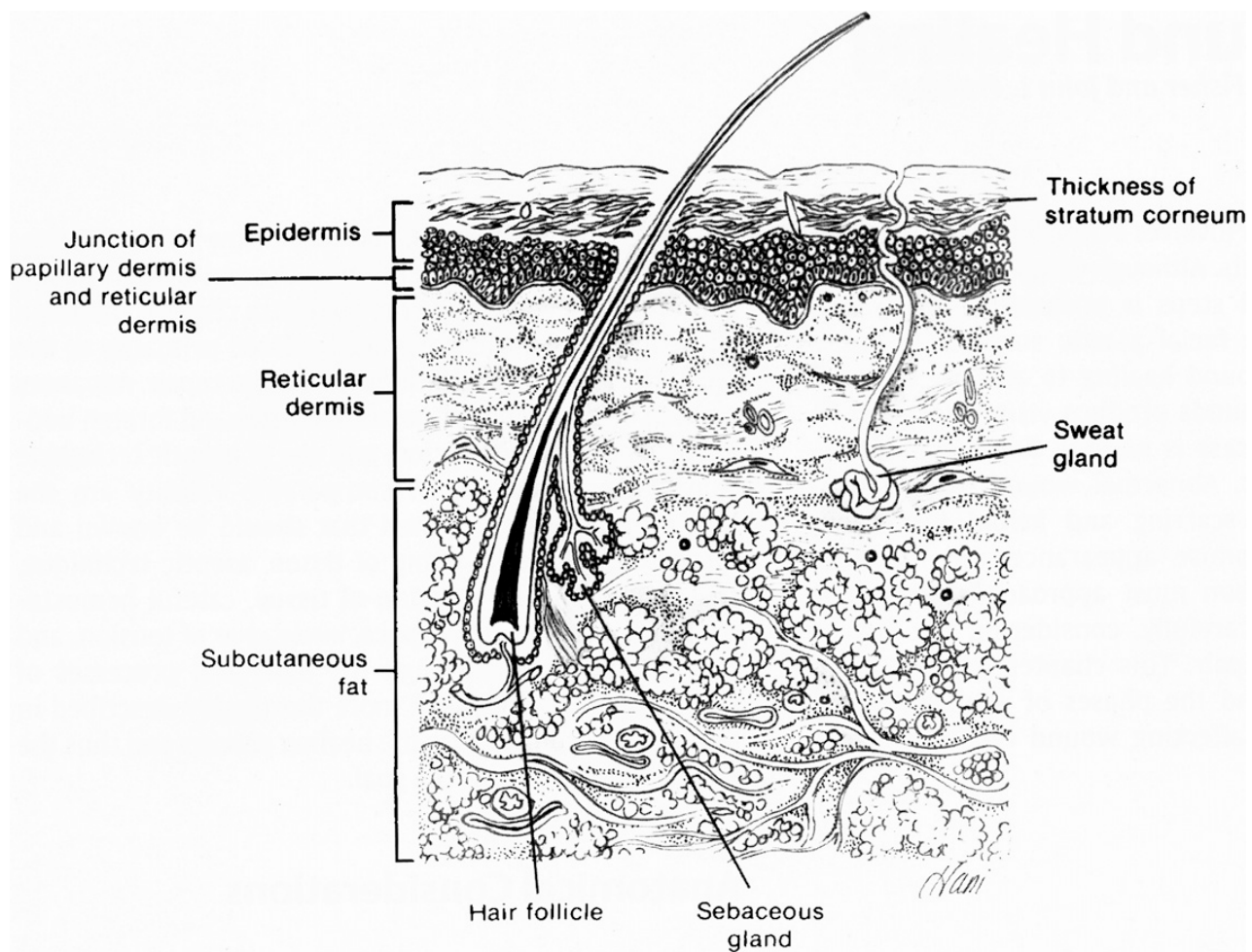
The maturation or remodeling phase begins approximately 3 weeks after injury. During this phase, type III collagen is replaced by type I

collagen, with reorientation of collagen fibers parallel to the scar, and regression of neovascularization. Scar tensile strength is ultimately 70% to 80% of that encountered in nonwounded skin.<sup>8,9</sup> The maturation phase can take up to 18 months after injury.

Yarborough<sup>10</sup> proposed that dermabrasion created a reorientation of collagen fibers parallel to the lines of wound tension, which may account for some of the scar contour smoothing effects noted after the procedure. Harmon and colleagues<sup>11</sup> performed ultrastructural evaluation of scars resulting from excision and primary closure of cutaneous malignancies in patients who underwent primary closure and those who underwent primary closure with dermabrasion. Serial punch biopsies over the course of 6 weeks showed organized unidirectional collagen fiber orientation parallel to the epidermal surface in the dermabrasion specimens, whereas the control specimens were found to have more-sparse and less-well-organized collagen fiber orientation.

### PREOPERATIVE CONSIDERATIONS

Surgeons should obtain a complete past medical history, including a current list of all medications, especially anticoagulants. Patients taking anticoagulants should discontinue these 2 weeks before dermabrasion if medically feasible. Acne scarring is



**Fig. 2.** Normal anatomy of the skin and appendages. (From Fisher E, Frodel J. Wound healing. In: Papel I, editor. Facial plastic and reconstructive surgery. New York: Thieme; 2009. p. 16; with permission.)

a common indication for dermabrasion, and therefore it is important to ask about recent or current use of isotretinoin (13-cis-retinoic acid; Accutane). Because of concerns regarding hypertrophic scarring and keloid formation, patients taking isotretinoin should discontinue this 6 to 12 months before dermabrasion.<sup>12</sup> Hydroquinone and retinoic acid may be prescribed to help prevent hyperpigmentation after dermabrasion.<sup>13–17</sup> Hydroquinone inhibits melanocyte conversion of tyrosine to 3,4-dihydroxyphenylalanine and is typically prescribed as a 4% topical cream or gel applied twice daily.<sup>18</sup> Retinoic acid (0.05% cream applied once daily) started 2 weeks before dermabrasion was shown by Mandy<sup>19</sup> to result in expedited reepithelialization. Additionally, he found that no patients who resumed once-daily topical 0.05% retinoic acid within 1 week of dermabrasion experienced post-operative postinflammatory hyperpigmentation or milia compared with 28% in the control group.<sup>19</sup> Prophylaxis against herpes simplex virus (HSV) outbreak should be considered in patients with a history to prevent reactivation. The authors do not typically use any preoperative medications

when performing dermabrasion for a limited facial scar.

## DERMABRASION

### Anesthesia

For traumatic and surgical scars, local anesthesia is preferred. The local anesthetic is injected into the dermis surrounding the scar and into the scar itself. The authors typically use a lidocaine with epinephrine solution. The injection provides tissue turgor, and the epinephrine minimizes oozing. Regional blocks may also be used, especially if a larger surface area is to be addressed.

### Skin Preparation

Proper skin tumescence helps maintain a uniform depth of dermabrasion and maximizes the surgeon's control of the dermabrader. Several methods can be used to accomplish this, including skin refrigerants, infiltration with local anesthetic, and mechanically stretching the skin surface to create skin tension. Special care must be undertaken when infiltrating with local anesthetic,



because this can distort important landmarks. The skin surface may be prepared with gentian violet or the ink from a marking pen; this is especially useful when dermabrading larger surface areas. Gentian violet or ink stains the epidermis, and therefore once the epidermis has been removed the surgeon no longer sees violet stain. In treating the multiple depressed and pitted scars resulting from acne, the violet color accentuates these areas after the first pass of the dermabrader. The surgeon should avoid using gauze, because it may become tangled within the dermabrader.

### Equipment

The dermabrader unit consists of the power source, hand piece, and cord (**Fig. 3**). Dermabrader hand pieces rotate between 10,000 to 50,000 revolutions per minute and are powered pneumatically or by electric motor. Diamond fraises or wire brushes of varying sizes are used to perform dermabrasion. Alternatively, manual dermabrasion may be undertaken using a wire brush, diamond fraise, or sterilized common sandpaper. Personal protective equipment, including eye protection and face-mask, are a necessity, because blood and tissue are aerosolized during the dermabrasion process.

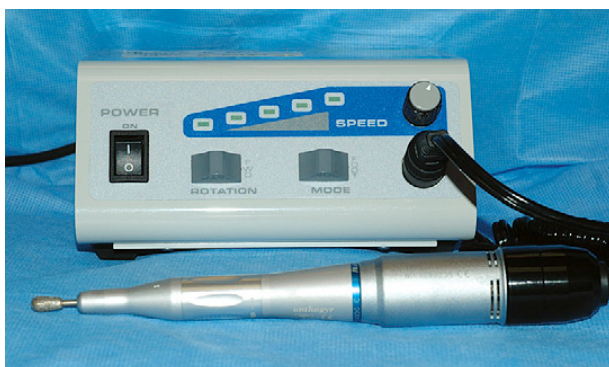### Technique

The dermabrader may be held like a pencil or with all four fingers around the handpiece, with the thumb toward the neck. The latter method was advocated by Yarborough<sup>20</sup> when using the wire brush, because it affords better control and minimizes the risk of ricochet of the device. This method is also used by the authors, although they typically use a diamond fraise. Yarborough<sup>20</sup> recommends pulling the wire brush in a unidirectional fashion and perpendicular to the plane of rotation. Bradley and Park<sup>21</sup> advocate that stroke direction should be 45° to the axis of the scar on

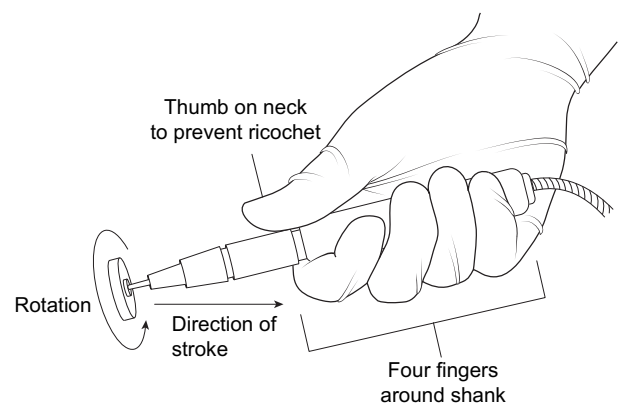
the first pass, and perpendicular to the axis of initial dermabrasion on subsequent passes. Again, the direction of motion should be perpendicular to the rotation of the fraise (**Fig. 4**). This technique maximizes control of the dermabrader and minimizes the risk of gouging. Special consideration must be given to the type of fraise used. Diamond fraises may be rotated clockwise or counterclockwise, whereas the wire brush may only be rotated clockwise.<sup>20,22</sup> Wire brush dermabrasion creates microscopic lacerations, which are oriented at right angles to one another, creating a micro-Z-plasty effect. The diamond fraise is more forgiving and less dependent on skin turgor than the wire brush.<sup>22</sup> For those with less experience, the diamond fraise is the safer option.

When dermabrading near mobile structures, such as the lip, nasal ala, or eyelids, care must be taken to orient the direction of fraise rotation toward these structures to prevent distortion. The esthetic boundary of the eyelids should be marked if they are in the field of view. Dermabrasion should never encroach on the eyelid skin, because this could be associated with disastrous complications. Minimizing blood and dermabrased debris on the skin surface is an important technical consideration. The former may be accomplished through beginning in gravity-dependent regions and working cephalically or centrally. The latter requires consideration of the direction of rotation of the fraise. As advocated by Bradley and Park,<sup>21</sup> moving a fraise rotating in the clockwise direction from left to right will result in deposition of debris behind the path of abrasion.

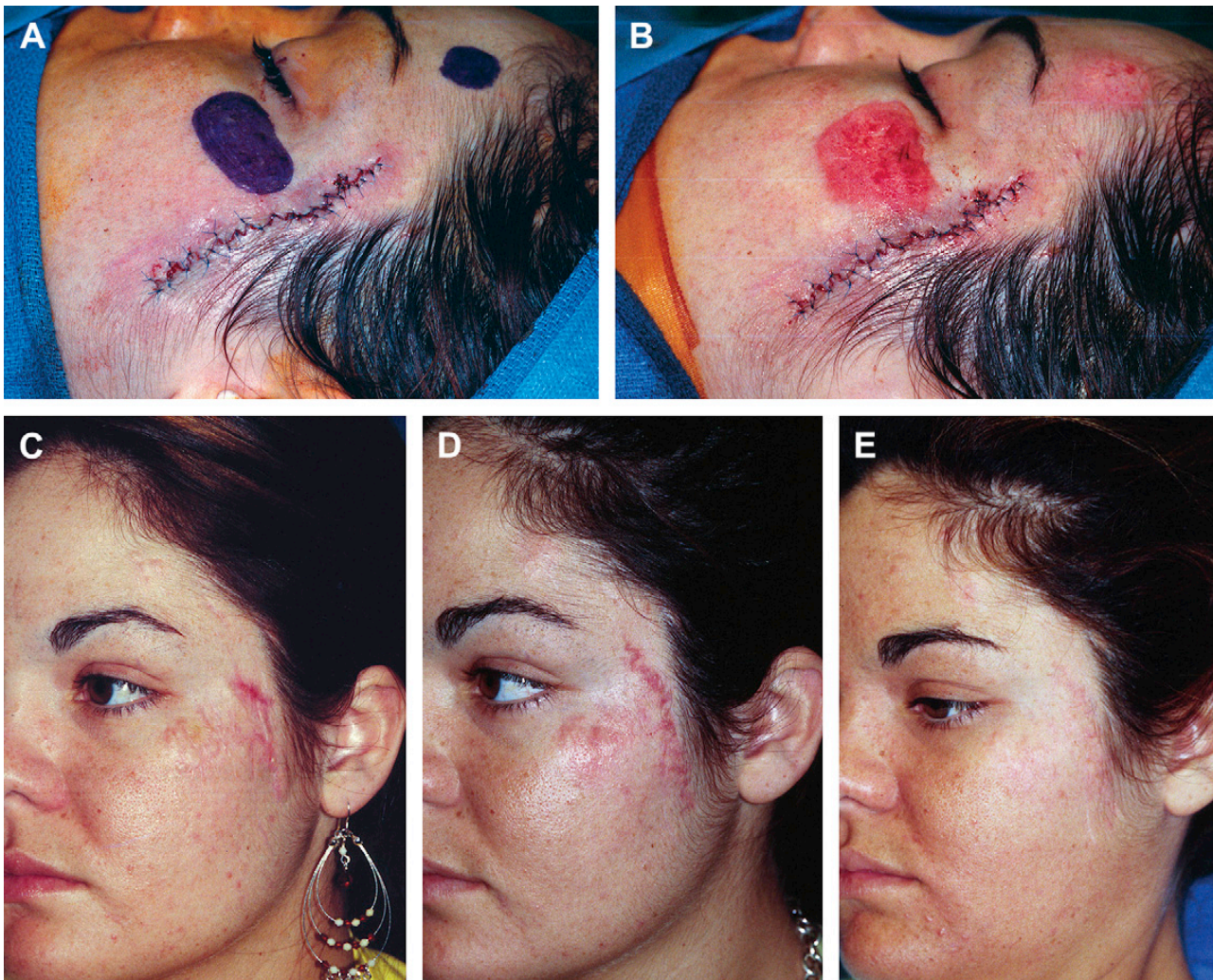Diffuse pinpoint bleeding heralds entry into the papillary dermis (**Fig. 5B**). A yellow chamois color marks the reticular dermis, with the superficial reticular dermis characterized by parallel oriented strands, and the deeper reticular dermis by frayed



**Fig. 3.** Dermabrader instrument demonstrating power source, cord, and dermabrader handle. A diamond fraise is attached.



**Fig. 4.** Dermabrader motion should remain perpendicular to the direction of fraise rotation. (From Yarborough JM Jr. Dermabrasion by wire brush. *J Dermatol Surg Oncol* 1987;13(6):610–5; with permission.)



**Fig. 5.** (A) Scars over left cheek and left forehead covered with ink from a marking pen. Adjacent skin shows immediate result after scar revision with geometric broken line closure. (B) Punctate bleeding noted in areas of dermabrasion. (C) Preoperative photograph showing irregular scars over the left cheek and left forehead and a hypertrophic left preauricular scar. (D) Early result (3 weeks) after dermabrasion and preauricular scar revision. (E) Results at 6 months after dermabrasion and scar revision.

white strands. Entry into the deep reticular dermis should be avoided because it is associated with scarring.<sup>23</sup> Careful depth control spares stem cells located within the adnexal structures that lie within the reticular dermis.

### POSTOPERATIVE CARE

Counseling patients regarding proper postoperative care is critical. Reepithelialization has been shown in animal models to be expedited through maintaining a moist wound, which optimizes epithelial migration,<sup>24</sup> and is maximized by using ointment or occlusive dressings. Complete reepithelialization usually occurs within 7 to 10 days after dermabrasion. Wounds may be left open or managed with occlusive dressings. Wounds left open require meticulous postoperative care involving frequent cleansing with mild soap and water, followed by application of ointment.

Occlusive dressings such as Vigilon (Bard Inc, Murray Hill, NJ, USA) have been shown to result in wounds that heal more rapidly and with less crusting than those left open.<sup>25</sup> After segmental or limited dermabrasion, the authors typically manage wounds in an open fashion with frequent cleansing followed by application of a mild ointment. Sun avoidance and frequent application of sunscreen are paramount. Erythema is expected, commonly lasts for weeks to months, and generally resolves with time.<sup>21</sup> If necessary, topical or systemic steroids can be used to decrease erythema in the postoperative period.<sup>26</sup>

### TIMING OF DERMABRASION

The timing of dermabrasion is variable. Yarborough<sup>10</sup> advocated early dermabrasion, ideally between 4 and 8 weeks postinjury. They theorized that scars treated earlier than 4 weeks had a tendency to



spread, because they lacked appropriate tensile strength. Katz and Oca<sup>27</sup> studied wound healing at 4, 6, and 8 weeks postinjury using diamond fraise dermabrasion, and reported the most optimal outcomes at 8 weeks. The authors theorized that an 8-week-old scar had more tensile strength than a 4- or 6-week-old scar, and consequently responded better to dermabrasion. Brenner and Perro<sup>18</sup> recommended that dermabrasion be performed 6 to 12 weeks after closure or reconstruction of skin cancer defects, because collagen remodeling is active during this time-frame.

## CASE STUDIES

### ***Patient 1: Facial Trauma: Lacerations and Deep Abrasions***

This patient is a 22-year-old woman who experienced facial lacerations and deep abrasions resulting from a motor vehicle accident. Areas of modest soft tissue loss also occurred. These areas healed through secondary intention. At 2 months postinjury, she was noted to have broad irregular scars involving the left cheek and left forehead. In addition, she had a 5.5 × 0.8 cm left preauricular hypertrophic scar. At 6 months after her injuries, the patient underwent dermabrasion of the left cheek and forehead scars. At the same time, a scar revision was performed for the left preauricular scar using the geometric broken line closure technique. A marking pen was used to identify the confines of the left cheek and forehead scars before dermabrasion (**Fig. 6A**). Dermabrasion was performed to the level of punctate bleeding

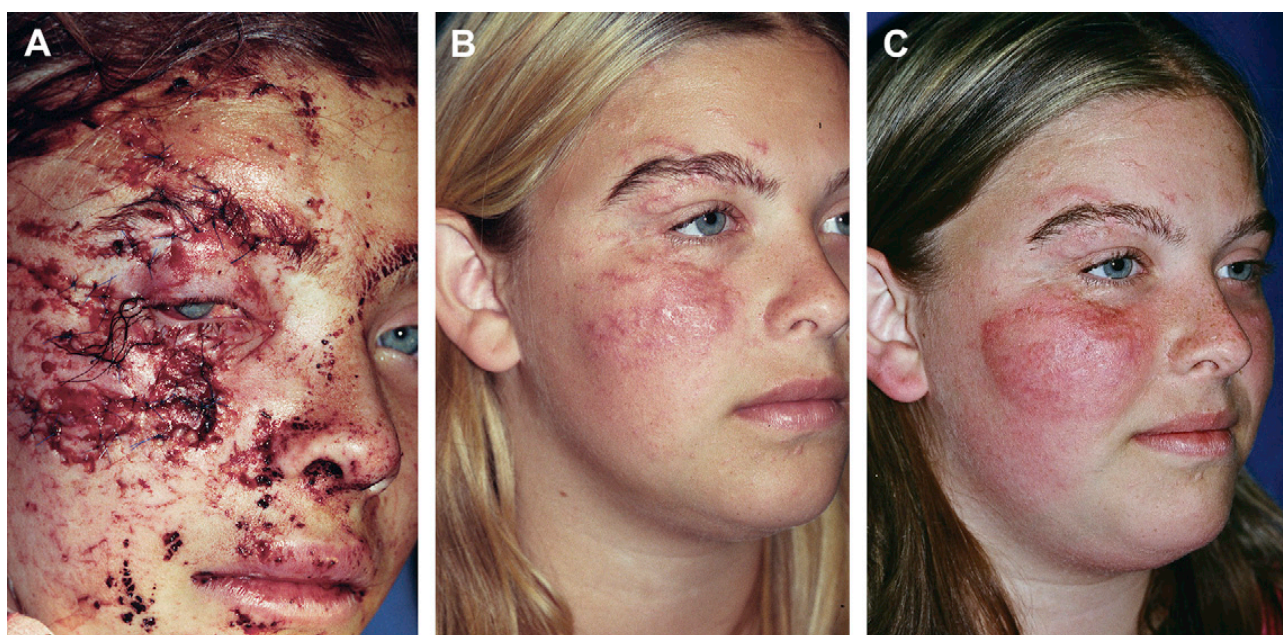(see **Fig. 6B**). The preoperative and postoperative results are shown in **Fig. 6C–E**.

### ***Patient 2: Facial Trauma: Multiple Facial Lacerations and Foreign Bodies***

This patient is a 13-year-old girl who was involved in a motor vehicle accident. Her injuries included multiple facial lacerations involving the right cheek and periorbital region. Multiple glass fragments were imbedded in the soft tissues. Foreign bodies were removed and the wounds were irrigated. The lacerations were closed primarily (see **Fig. 5A**). The resulting scars were broad, nodular, and hyperemic (see **Fig. 5B**). Dermabrasion was performed 24 months after the initial injury and resulted in improvement in the texture and contour of the skin, although persistent erythema was still visible at 6 months after dermabrasion (see **Fig. 5C**).

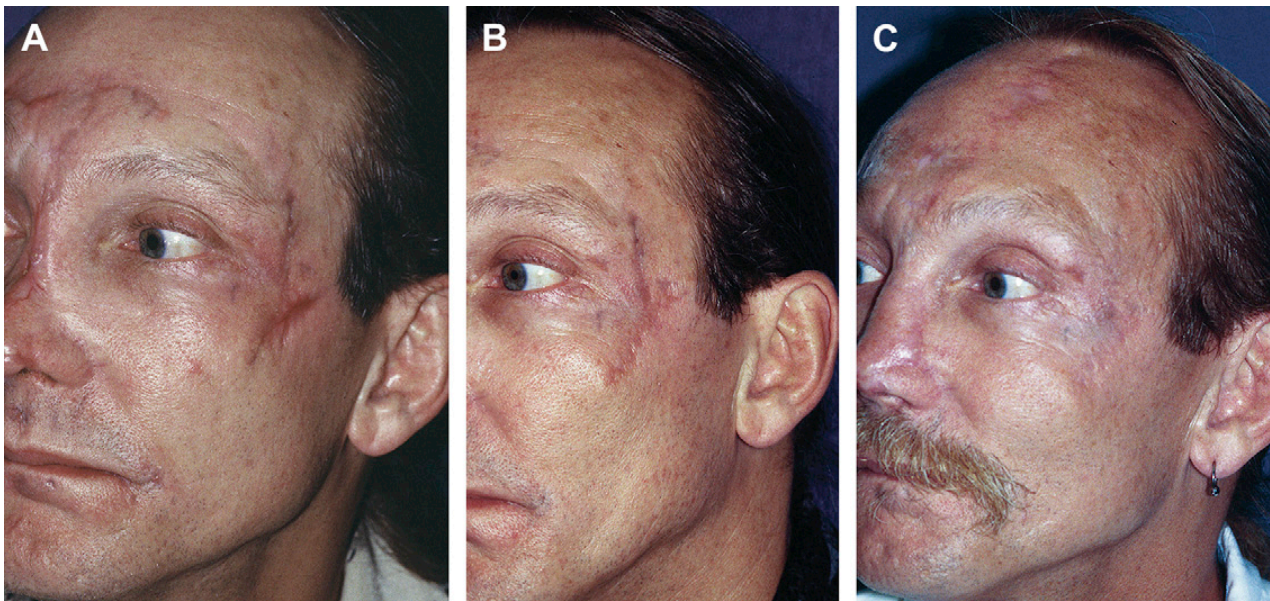
### ***Patient 3: Facial Trauma: Extensive Soft Tissue Injury***

This patient is a 51-year-old man who is a tattoo artist. He lost control of his motorcycle and experienced extensive soft tissue injuries, including full thickness skin loss over the nasal dorsum and right forehead. Multiple reconstructive procedures were required for these defects and the resulting scars. One of his posttraumatic deformities included a wide 5.5-cm scar over the left cheek (**Fig. 7A**). At 3 months after his injury, a scar revision procedure was performed, consisting of excision of the scar and repair with a running W-plasty (see



**Fig. 6.** (A) Multiple facial lacerations immediately after primary repair. (B) Broad irregular scars involving right cheek and right periorbital region 10 months after the initial injury. (C) Improved contour and texture of right cheek 6 months after dermabrasion with mild persistent erythema.





**Fig. 7.** (A) Wide erythematous scar left cheek. (B) Early result after excision with W-plasty scar revision. (C) Final result 1 year after scar revision and dermabrasion (performed 3 months after scar revision).

**Fig. 7B).** The resultant scar was further improved with dermabrasion, performed 3 months after the scar revision, at the time of other reconstructive procedures (see **Fig. 7C**).

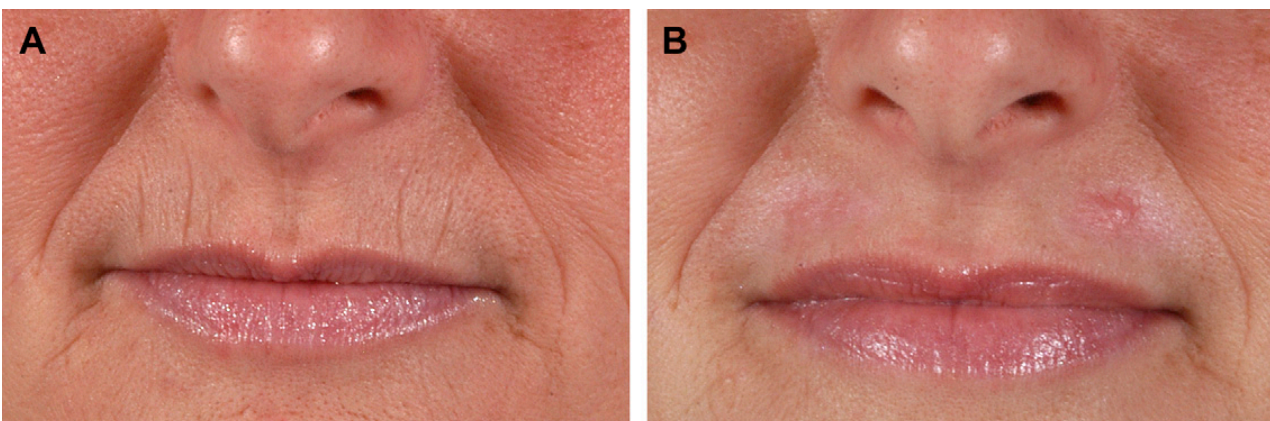#### COMPLICATIONS OF DERMABRASION

The most dreaded and avoidable complication of dermabrasion is scarring. Scarring is caused by working too deeply, which damages adnexal structures and compromises the reepithelialization process.

Hypertrophic scarring and keloid formation are potential complications, and therefore it is important to ask patients about any history of structures such as surgical scars or traumatic scars. **Fig. 8A** illustrates a patient with perioral rhytids who developed hypertrophic scar formation after dermabrasion by a colleague of the senior author. **Fig. 8B** shows improvement of perioral rhytids with

postoperative hypertrophic scar formation, which was ultimately excised and closed primarily.

Concern also exists regarding the effect of isotretinoin on hypertrophic scar and keloid formation because of its suppressive effect on the sebaceous glands.<sup>28–30</sup> Sebaceous glands play a critical role in the reepithelialization process. Studies by Rubenstein and colleagues<sup>31</sup> in 1986 and Katz and colleagues<sup>32</sup> in 1994 showed poor outcomes (ie, hypertrophic scarring and keloid formation) after dermabrasion in the setting of recent isotretinoin use. Rivera<sup>12</sup> advocated stopping isotretinoin at least 6 to 12 months before any planned dermabrasion. More recently, Bagatin and colleagues<sup>33</sup> performed manual dermabrasion (not powered) using a diamond fraise on seven patients, all actively taking oral isotretinoin at dermabrasion. They observed no abnormal scarring or keloid formation in this study population, and suggested that the immunologic and



**Fig. 8.** (A) Preoperative photograph showing perioral rhytids before dermabrasion. (B) Postoperative result showing improvement of perioral rhytids with development of hypertrophic scar on left upper lip.



inflammatory response may play more of a role in postdermabrasion scarring and keloid formation than isotretinoin. Although the literature is equivocal, isotretinoin use warrants special consideration. Until definitive evidence suggests otherwise, the authors advocate discontinuing isotretinoin at least 6 to 12 months before dermabrasion.

Hyperpigmentation is more common in dark-skinned patients, and can be exacerbated by estrogen use and sun exposure. Hyperpigmentation usually resolves within 3 to 6 months and may also be treated with a topical application of 4% hydroquinone and 0.05% retinoic acid. Hypopigmentation usually occurs within 1 to 2 months and is also more common in dark-skinned patients. This effect will usually resolve over 6 to 10 weeks; however, no medical treatment exists for hypopigmentation. Makeup may be the only remedy in these circumstances.

Milia is a condition of small inclusion cysts within the epidermis, which can be directly excised and also responds to retinoids. In a prospective series, Mandy<sup>19</sup> noted a significantly lower postoperative incidence of milia (and postinflammatory hyperpigmentation) in patients treated with 0.05% topical retinoic acid applied once daily started within 1 week after dermabrasion compared with controls not given postoperative retinoids.

Patients should also be counseled about the risks of bleeding and infection. The most common infectious organisms are *Staphylococcus aureus*, HSV, and *Candida*. Staphylococcal infection most often presents with edema, honey crusting, and fevers within 48 to 72 hours postoperatively. HSV reactivation is recognized as pain disproportionate to the examination within 48 to 72 hours postoperatively. Patients with a known history of HSV infection should be treated prophylactically to prevent reactivation. Valacyclovir (500 mg by mouth twice daily) or similar antiviral medications may be started the day before or the day of surgery, with several studies advocating a 10-day postoperative course.<sup>34–36</sup> *Candida* infections tend to manifest later, usually at 5 to 7 days, with the hallmarks being delayed healing, edema, and exudates. Eczema and dermatitis occur in up to 10% of patients and can be treated with topical, intralesional, or systemic steroids.<sup>21</sup>

## SUMMARY

Dermabrasion remains an effective adjunct to scar revision. It is a well-established technique with well-studied outcomes. In contrast to carbon dioxide laser resurfacing, dermabrasion has lower capital investment costs, lower maintenance

costs, a better safety profile, and can be used in almost any outpatient setting.

## REFERENCES

1. Lawrence N, Mandy S, Yarborough J, et al. History of dermabrasion. *Dermatol Surg* 2000;26(2):95–101.
2. Goslen J. Physiology of wound healing and scar formation. In: Thomas J, Holt G, editors. *Facial scars: incision, revision, and camouflage*. St Louis (MO): CV Mosby; 1989. p. 12.
3. Kanzler MH, Gorsulowsky DC, Swanson NA. Basic mechanisms in the healing cutaneous wound. *J Dermatol Surg Oncol* 1986;12(11):1156–64.
4. Pierce GF. Macrophages: important physiologic and pathologic sources of polypeptide growth factors. *Am J Respir Cell Mol Biol* 1990;2(3):233–4.
5. Fisher E, Frodel J. Wound healing. In: Papel I, editor. *Facial plastic and reconstructive surgery*. New York: Thieme; 2009. p. 15–25.
6. Krawczyk WS. A pattern of epidermal cell migration during wound healing. *J Cell Biol* 1971;49(2):247–63.
7. Gourin C, Terris D. Dynamics of wound healing. In: Bailey B, Johnson J, editors. *Head and neck surgery—otolaryngology*. Philadelphia: Lippincott Williams & Wilkins; 2006. p. 197–213.
8. Goslen JB. Wound healing for the dermatologic surgeon. *J Dermatol Surg Oncol* 1988;14(9):959–72.
9. Levenson SM, Geever EF, Crowley LV, et al. The healing of rat skin wounds. *Ann Surg* 1965;161:293–308.
10. Yarborough JM Jr. Ablation of facial scars by programmed dermabrasion. *J Dermatol Surg Oncol* 1988;14(3):292–4.
11. Harmon CB, Zelickson BD, Roenigk RK, et al. Dermabrasive scar revision. Immunohistochemical and ultrastructural evaluation. *Dermatol Surg* 1995;21(6):503–8.
12. Rivera AE. Acne scarring: a review and current treatment modalities. *J Am Acad Dermatol* 2008;59(4):659–76.
13. Spencer M. Topical use of hydroquinone for depigmentation. *JAMA* 1965;194(9):962–4.
14. Palumbo A, d'Ischia M, Misuraca G, et al. Mechanism of inhibition of melanogenesis by hydroquinone. *Biochim Biophys Acta* 1991;1073(1):85–90.
15. Grimes PE. Management of hyperpigmentation in darker racial ethnic groups. *Semin Cutan Med Surg* 2009;28(2):77–85.
16. Ortonne JP. Retinoic acid and pigment cells: a review of in-vitro and in-vivo studies. *Br J Dermatol* 1992;127(Suppl 41):43–7.
17. Kaplan B, Potter T, Moy RL. Scar revision. *Dermatol Surg* 1997;23(6):435–42 [quiz: 443–4].
18. Brenner MJ, Perro CA. Recontouring, resurfacing, and scar revision in skin cancer reconstruction. *Facial Plast Surg Clin North Am* 2009;17(3):469–87, e3.

19. Mandy SH. Tretinoin in the preoperative and postoperative management of dermabrasion. *J Am Acad Dermatol* 1986;15(4 Pt 2):878–9, 888–9.
20. Yarbrough JM Jr. Dermabrasion by wire brush. *J Dermatol Surg Oncol* 1987;13(6):610–5.
21. Bradley DT, Park SS. Scar revision via resurfacing. *Facial Plast Surg* 2001;17(4):253–62.
22. Alt TH. Facial dermabrasion: advantages of the diamond fraise technique. *J Dermatol Surg Oncol* 1987;13(6):618–24.
23. Koranda F. Dermabrasion. In: Thomas JR, Roller J, editors. *Cutaneous facial surgery*. New York: Thieme; 1992. p. 104.
24. Winter GD. Formation of the scab and the rate of epithelization of superficial wounds in the skin of the young domestic pig. *Nature* 1962;193:293–4.
25. Mandy SH. A new primary wound dressing made of polyethylene oxide gel. *J Dermatol Surg Oncol* 1983;9(2):153–5.
26. Bernstein LJ, Kauvar AN, Grossman MC, et al. The short- and long-term side effects of carbon dioxide laser resurfacing. *Dermatol Surg* 1997;23(7):519–25.
27. Katz BE, Oca AG. A controlled study of the effectiveness of spot dermabrasion ('scarabrasion') on the appearance of surgical scars. *J Am Acad Dermatol* 1991;24(3):462–6.
28. Goldstein JA, Comite H, Mescon H, et al. Isotretinoin in the treatment of acne: histologic changes, sebum production, and clinical observations. *Arch Dermatol* 1982;118(8):555–8.
29. Nelson AM, Zhao W, Gilliland KL, et al. Early gene changes induced by isotretinoin in the skin provide clues to its mechanism of action. *Dermatoendocrinol* 2009;1(2):100–1.
30. Nelson AM, Zhao W, Gilliland KL, et al. Temporal changes in gene expression in the skin of patients treated with isotretinoin provide insight into its mechanism of action. *Dermatoendocrinol* 2009;1(3):177–87.
31. Rubenstein R, Roenigk HH Jr, Stegman SJ, et al. Atypical keloids after dermabrasion of patients taking isotretinoin. *J Am Acad Dermatol* 1986;15(2 Pt 1):280–5.
32. Katz BE, MacFarlane DF. Atypical facial scarring after isotretinoin therapy in a patient with previous dermabrasion. *J Am Acad Dermatol* 1994;30(5 Pt 2):852–3.
33. Bagatin E, dos Santos Guadanhim LR, Yarak S, et al. Dermabrasion for acne scars during treatment with oral isotretinoin. *Dermatol Surg* 2010;36(4):483–9.
34. Gilbert S, McBurney E. Use of valacyclovir for herpes simplex virus-1 (HSV-1) prophylaxis after facial resurfacing: a randomized clinical trial of dosing regimens. *Dermatol Surg* 2000;26(1):50–4.
35. Beeson WH, Rachel JD. Valacyclovir prophylaxis for herpes simplex virus infection or infection recurrence following laser skin resurfacing. *Dermatol Surg* 2002;28(4):331–6.
36. Gilbert S. Improving the outcome of facial resurfacing—prevention of herpes simplex virus type 1 reactivation. *J Antimicrob Chemother* 2001;47(Suppl T1):29–34.